

## ORIGINAL ARTICLE

**Comparison of T2 Dixon and Standard Sagittal MRI Sequences for Evaluating Lumbar Spine Degeneration**Sobia Jawwad Raza<sup>1</sup>, Madiha<sup>1</sup>, Muhammad Ikram<sup>2</sup>, Nadia Gul<sup>1\*</sup>, Farkhanda Jabeen<sup>3</sup>, Anum Ajmal<sup>4</sup>**ABSTRACT**

**Objective:** To evaluate the diagnostic performance and inter observer agreement between standard sagittal protocol and Dixon protocol in assessment of high intensity zones and Modic end plate changes in patients who undergo magnetic resonance imaging of lumbar spine for lumbar radiculopathy.

**Study Design:** Cross-sectional study.

**Place and Duration of Study:** The study was conducted at the Department of Diagnostic Radiology, Wah Medical College Wah Cantt, Pakistan in period of three months from March 2024 to May 2024.

**Methods:** Total 163 patients of either gender above age of 30 years were included in the study presented with complaint of lumbar radiculopathy. All patients underwent magnetic resonance imaging of lumbar spine. Two experienced radiologists first assessed the high intensity zones and Modic end plate changes for each level of lumbar spine on the sagittal T2 Dixon sequences and then on standard sagittal sequences independently from one another. Findings were recorded on performa. Data was analyzed using SPSS version 23. First the agreement between readers 1 and 2 was examined for the Dixon protocol and then on standard protocol in assessment of high intensity zone and Modic end plate changes using kappa statistics and the size of the inter-reader agreement was compared between standard protocol and Dixon protocol. Secondly the K values and their standard errors were used to perform a Z-test to examine if there are significant statistical differences between the two sequences.

**Results:** Both the Dixon and standard protocols demonstrate high inter observer agreement with Cohen's Kappa values indicating almost perfect concordance. The Z-test comparisons between the protocols show no statistically significant differences in agreement for either high intensity zones or Modic end plate changes assessments at any spinal level, as all *P*-values were above the 0.05 threshold. Both protocols exhibit comparable reliability in evaluating lumbar spine conditions.

**Conclusion:** Single sagittal T2 Dixon sequence could replace the standard sagittal sequences for the assessment of high intensity zones and Modic end plate changes with a 30% acquisition time reduction at 1.5T.

**Keywords:** Lumbar spine, Magnetic Resonance Imaging, Radiculopathy.

**How to cite this:** Raza SJ, Madiha, Ikram M, Gul N, Jabeen F, Ajmal A. Comparison of T2 Dixon and Standard Sagittal MRI Sequences for Evaluating Lumbar Spine Degeneration. *Life and Science*. 2024; 5(4): 511-519. doi: <http://doi.org/10.37185/LnS.1.1.759>

This work is licensed under a Creative Commons Attribution-NonCommercial 4.0 International license. (<https://creativecommons.org/licenses/by-nc/4.0/>). Non-commercial uses of the work are permitted, provided the original work is properly cited.

<sup>1</sup>Department of Radiology/Orthopedic<sup>2</sup>/ENT<sup>4</sup>  
POF Hospital Wah Cantt, Pakistan  
Wah Medical College Wah Cantt, Pakistan

<sup>3</sup>Department of Radiology  
Pakistan Institute of Medical Sciences (PIMS) Islamabad  
Pakistan

Correspondence:

Dr. Nadia Gul  
Associate Professor, Radiology  
POF Hospital Wah Cantt, Pakistan  
Wah Medical College Wah Cantt, Pakistan  
E-mail: [mrsnadiagul375@gmail.com](mailto:mrsnadiagul375@gmail.com)

Received: April 12, 2024; Revised: Aug 18, 2024

Accepted: Sep 03, 2024

**Introduction**

Low backache is common problem nowadays and managed primarily by primary health care. The prevalence of backache in Pakistan is 12% and main cause of backache is degenerative changes in lumbar spine (85%). Imaging is suggested only if there are red flag signs or if pain is resistant to conservative management of about 6 weeks.<sup>1,2</sup>

Magnetic resonance imaging (MRI) is most valuable

imaging modality for uncovering underlying pathology.<sup>3</sup> Intervertebral disc (IVD) degeneration, fatty atrophy of paraspinal muscles and vertebral end plate changes are the most common causes of low backache. IVD is composed of inner nucleus pulposus turning hyperintense signal and outer rim of annulus fibrosus returning hypointense signal on T2WI sequence. High intensity zones (HIZs) also known as annular tears appear as T2WI hyperintense signal in annulus fibrosus.<sup>4,5</sup> Disc degeneration is graded on T2WI sagittal sequence according to Pfirrmann or modified Pfirrmann grading system.<sup>6-8</sup> There are three types of end plate degenerative changes according to Modic et al. manifesting as bone marrow edema on opposing end plates (type I), fatty marrow conversion (type II) and subchondral bone sclerosis (type III). Modic end plate changes (MEPC) are assessed on sagittal sequences of MRI spine.<sup>9</sup> Approximately 22% of patients with low back pain show Modic type I and II degenerative changes.<sup>10</sup>

While acquisition protocols of lumbar spine can vary, there is a common consensus that the standard protocol for mechanical low back pain should include a combination of sagittal T1 weighted imaging (T1WI) and sagittal T2 weighted imaging (T2WI), sagittal T2 short to inversion recovery (STIR) and axial T1WI and T2WI sequences with T2WI myelography.<sup>11,12</sup> Marrow signals, HIZ, MEPC and foraminal stenosis are usually assessed on sagittal images and disc herniation and lateral recesses and spinal canal stenosis are assessed on axial images.<sup>13,14</sup>

The Dixon technique based on chemical shift between protons of water and fat generates a set of four images that comprises of in phase (in), opposed phase (oppo), water only (WO) and fat only (FO) images in one acquisition, thus resulting in significant time reduction. A recent study has demonstrated that T2-weighted Dixon imaging could provide similar diagnostic performance to that of T1-weighted, T2-weighted and fat suppressed

sequences for the detection of bone marrow metastases.<sup>15-18</sup>

As Dixon is an emerging technique in evaluation of degenerative changes in spine, very limited literature is available in Pakistan. The aim of our study is to assess whether the Dixon T2WI sagittal sequence can replace standard sagittal sequences without loss of diagnostic information, thus resulting in less acquisition time.

## Methods

The cross sectional study was conducted at the Department of Diagnostic Radiology, Wah Medical College Wah Cantt, Pakistan in period of three months from March 2024 to May 2024 after taking ethical committee approval from the hospital vide letter no: IRB/24/2024 on dated: 10<sup>th</sup> May 2024. The sample size was 163, calculated by using WHO sample size calculator taking prevalence of backache 12%,  $Z=1.96$  and alpha value of 0.05. Thus total 163 patients of either gender above age of 30 years were included in study presented with complaints of lower backache and lumbar radiculopathy. Patients in whom MRI is contraindicated or having history of spinal surgery, scoliosis, infection, fractures and neoplastic and hematopoietic disorders were excluded from study. All patients underwent MRI lumbar spine in Syngo via Siemens Medical system Germany 1.5 T with imaging parameters as shown in table-1.

## Data Analysis Procedure

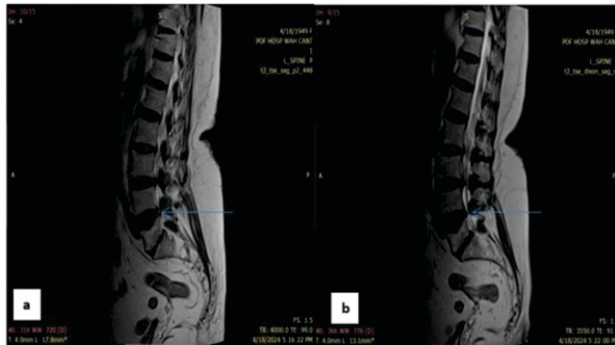
Two radiologists each having at least 5 years experience first assessed the HIZs and MEPC for each level of lumbar spine on the sagittal T2 Dixon sequences that include T2 Dixon fat only (FO), in phase and water only (WO) and then on standard sagittal sequences that include T1WI, T2WI and T2 STIR independently from one another. A meeting was arranged prior to study initiation to standardize the readings on an independent database. Clinical information (gender, age, indication) was noted and available to the readers in both protocols. All discs

**Table-1: Imaging parameters for standard and Dixon sagittal sequences**

	TR ms	TE ms	TI ms	Slice thickness mm	FOV mm	Matrix	Acquisition time (s)
T1WI sagittal	650	10	-	4	330	384x384	1:55
T2WI sagittal	4000	99	-	4	330	448x448	1:26
STIR sagittal	4000	39	160	4	330	384x384	1:50
Dixon T2WI sagittal	3550	91	-	4	330	320x320	3:27

TR: time to recall, TE: time to echo, TI: inversion time, ms: milliseconds, mm: millimeter, s: seconds Total time for all three sagittal sequences is 5:11s and for sagittal Dixon sequence is 3:27s thus 34% time reduction by using Dixon protocol

levels from L1 through L5-S1 (total 815 discs) were evaluated for presence and absence of HIZs on sagittal T2WI and sagittal Dixon T2WI in phase acquisition as hyperintensity in posterior annulus as shown in figure.1. If absent, the response was recorded as No and if present, the response was recorded as Yes.

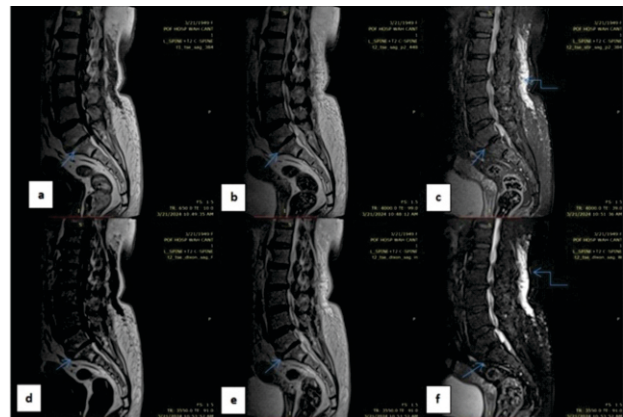


**Fig.1: High intensity zone (HIZ) appearing as small focal hyperintensity in intervertebral disc posteriorly on standard protocol T2WI (a) and on Dixon protocol in phase (b)**

All disc levels from L1 through L5-S1 (total 815 discs) were assessed for absence and presence of MEPC with their grading on Dixon protocol and standard protocol in two sets as shown in figure.2.

If absent, the response was recorded as No and if present, the response was recorded as Modic I, II, III or mixed Modic (any combination of I, II & III) according to Modic et al. as detailed below.<sup>9</sup>

1. Modic I: end plate hypointensity on T1WI & Dixon T2 FO, hyperintensity on T2WI & Dixon T2 in phase and hyperintensity on STIR & Dixon T2 WO



**Fig.2: First row: standard protocol, (a) T1WI, (b) T2WI, © T2STIR**

Second row: T2 Dixon protocol, (d) fat only FO, (e) T2 in phase, (f) water only WO Straight arrows are showing Modic type II changes at L5-S1 level, it is evident that fat signals are brighter on T2dixon fat only (d) as compared to T1WI images (a) Curved arrows are showing subcutaneous tissue edema which is more evident on T2dixon water only (f) as compared to T2STIR (c)

2. Modic II: end plate hyperintensity on T1WI & Dixon T2 FO, hyperintensity on T2WI & Dixon T2 in phase, hypointensity on STIR & Dixon T2 WO
3. Modic III : end plate hypointensity on T1WI & Dixon T2 FO, hypointensity on T2WI & Dixon T2 in phase, hypointensity on STIR & Dixon T2 WO

Findings were recorded on performa. Data was analyzed using SPSS version 23. First the agreement between readers 1 and 2 was examined for the Dixon protocol and standard protocol in assessment of HIZs and MEPC using kappa statistics and the size of the inter-reader agreement was compared between standard protocol and Dixon protocol. Secondly the k values and their standard errors were used to perform a z-test to examine if there are significant statistical differences between the two sequences.

## Results

There were total of 163 patients included in the study. The mean age of the patients was 53.99 ± 13.17 years, the median age was 55, the mode was 58 and the range was 62 (minimum: 22 and maximum: 84 years). There were 93 (57.06%) females and 70 (42.94%) males.

Table 2 shows the reliability of the Dixon Protocol in assessing high-intensity zones (HIZ) across different lumbar spine levels. Specifically, for HIZ at L1-L2, the agreement between Reader 1 and Reader 2 yielded a Cohen's Kappa value of 0.89 ( $P < .001$ ). For HIZ at L2-L3, the kappa value was 0.86 ( $P < .001$ ), indicating almost perfect concordance. At L3-L4, the agreement was particularly high, with a kappa value of 0.94 ( $P < .001$ ). Similarly, HIZ assessment at L4-L5 showed a kappa value of 0.88 (standard error 0.04,  $P < .001$ ), and at L5-S1, the kappa value was 0.87 (standard error 0.03,  $P < .001$ ).

Table-3 shows the analysis using the Dixon Protocol for Modic Endplate Change (MEPC) assessment. There is an almost perfect agreement between Reader 1 and Reader 2 at various lumbar spine levels. For instance, at L1-L2, the agreement demonstrated by Cohen's Kappa was 0.84 ( $P < .001$ ). Similarly, the kappa value for L2-L3 was 0.85 ( $P < .001$ ), indicating very high concordance. The consistency in assessment was also evident at L3-L4, with a kappa value of 0.86 ( $P < .001$ ). Both L4-L5 and L5-S1 maintained a kappa value of 0.86, each with a standard error of 0.04 ( $P < .001$ ).

Table-4 shows; there was an almost perfect agreement between Reader 1 and Reader 2 in assessing high-intensity zones (HIZ) across the lumbar spine. At L1-L2, Cohen's Kappa value was 0.89 ( $P < .001$ ), reflecting a very strong concordance. For L2-L3, the kappa value was 0.83 ( $P < .001$ ). At L3-L4, the agreement was similarly high, with a kappa value of 0.86 ( $P < .001$ ). Both L4-L5 and L5-S1 demonstrated kappa values of 0.82 and 0.84, respectively, each with a standard error of 0.04 ( $P < .001$ ).

The analysis using the Standard Protocol for Modic Endplate Change (MEPC) assessment showed almost perfect agreement between Reader 1 and Reader 2 which was demonstrated at all lumbar spine levels. At L1-L2, Cohen's Kappa revealed a high concordance with a value of 0.85 ( $P < .001$ ). Similarly, for L2-L3, the

kappa value was also 0.86 ( $P < .001$ ), indicating consistent agreement between the readers. This trend continued at L3-L4, where the kappa value increased slightly to 0.88 ( $P < .001$ ), reflecting even stronger agreement. At L4-L5, the agreement remained high, with a kappa value of 0.87 ( $P < .001$ ). Finally, at L5-S1, the kappa value was 0.88, with a standard error of 0.03 ( $P < .001$ ).

Both the Dixon and Standard protocols demonstrate high agreement for assessing High Intensity Zones (HIZ) and Modified Endplate Change (MEPC) across all lumbar spine levels (L1 to S1) with Cohen's Kappa values indicating almost perfect concordance. The Z-test comparisons between the protocols show no statistically significant differences in agreement for either HIZ or MEPC assessments at any spinal level, as all p-values are above the 0.05 threshold. Both protocols exhibit comparable reliability in evaluating lumbar spine conditions.

## Discussion

Both the Dixon and Standard protocols demonstrate high agreement among readers for assessing High-Intensity Zones (HIZ) and Modic Endplate Changes (MEPC) across all lumbar spine levels (L1-S1), with Cohen's Kappa values indicating almost perfect concordance. The Z test comparisons between the protocols show no statistically significant differences in agreement for either HIZ or MEPC assessments at any spinal level. Similar results are seen in study conducted by Saifuddin A et al. showing that inter-reader agreement for MEPC on the routine protocol was 0.45 and for the Dixon protocol was 0.53 ( $P = 0.02$ ), and inter-reader agreement for identification of the HIZ on the routine protocol was 0.52 and for the Dixon protocol was 0.46 ( $P = 0.27$ )<sup>15</sup> Similarly, another study by Zanchi F et al. also shows that single sagittal T2-weighted Dixon sequence may replace the recommended combination of T1WI, T2WI, and fat-suppressed T2-weighted sequences.<sup>16</sup>

Our study has also shown that commonly involved levels by Modic changes and HIZs were L4-L5 and L5-S1. Modic type II changes are common followed by type I and least common are Modic type III. Similar results are shown by study conducted by Chen, Y et al. in which modic type II changes are common and commonly involved levels are L4-L5 and L5-S1.<sup>17-19</sup> Systematic literature reviews on the distribution of HIZ in lumbar spine have shown that multilevel HIZs

**Table-2: Inter-Reader Agreement for High-Intensity Zones (HIZ) in the Lumbar Spine using the Dixon Protocol**

		Yes	No	Total	Cohen's Kappa	Standard Error	P-value
Dixon Protocol Reader 1: LIZ L1-L2							
Dixon Protocol Reader 2: HIZ L1-L2	Yes	4	1	5	0.886	0.113	<.001
	No	0	158	158			
Dixon Protocol Reader 1: LIZ L2-L3							
Dixon Protocol Reader 2: HIZ L2-L3	Yes	10	1	11	0.86	0.080	<.001
	No	2	150	152			
Dixon Protocol Reader 1: LIZ L3-L4							
Dixon Protocol Reader 2: HIZ L3-L4	Yes	29	0	29	0.94	0.035	<.001
	No	3	131	134			
Dixon Protocol Reader 1: LIZ L4-L5							
Dixon Protocol Reader 2: HIZ L4-L5	Yes	71	3	74	0.88	0.04	<.001
	No	7	82	89			
Dixon Protocol Reader 1: LIZ L5-S1							
Dixon Protocol Reader 2: HIZ L5-S1	Yes	61	5	66	0.87	0.03	<.001
	No	5	92	97			

*HIZ: high intensity zone, L1-L2: lumbar vertebra 1 and 2, L2-L3: lumbar vertebra 2 and 3, L3-L4: lumbar vertebra 3 and 4, L4-L5: lumbar vertebra 4 and 5, L5-S1: lumbar vertebra 5 and sacral vertebra 1.*

contribute in backache and accelerate the process of disc degeneration.<sup>20,21</sup> Modic type I and II end changes are also associated with low back pain. Therefore, the importance of identifying HIZ and MEPC are crucial for appropriate management.<sup>22</sup> In our study, inter-reader agreement for MEPC and HIZ was significantly better on the T2 Dixon sequence as compared to standard sagittal sequences. Fat containing lesions like hemangiomas and modic type II changes i.e. end plate fat metaplasia was more avid on T2Dixon FO sagittal sequence than on T1WI as shown in figure 2 (a) and (d). Our findings are consistent with the studies conducted by Huang H et al. and Allam M.F.AB et al. showing that subchondral fatty metaplasia in sacroiliitis is better appreciated on T2Dixon FO images than on T1WI.<sup>23,24</sup> Similarly, T2 Dixon WO sequences show better fat suppression than standard T2 STIR sequence thus

making edema signal more evident as shown in figure 2 (c) and (f). Active bone erosions and tumors are also more evident on Dixon FS than STIR due to homogenous fat suppression and high signal to noise ratio.<sup>25</sup> There are few limitations to our study. We have focused only on sagittal sequences, HIZ and MEPC. Marrow signals of vertebral bodies are routinely assessed on sagittal T1WI sequences. Although the main focus of our study was degenerative changes of lumbar spine, any incidental finding of neoplastic or myeloproliferative disorder lesion in spine can never be missed by replacing the T1WI by T2Dixon because according to the study by Sasiponganan C et al. T2 weighted Dixon imaging is capable of effectively distinguishing between yellow marrow, red marrow, and various osseous lesions, whether benign or malignant.<sup>26</sup>

**Table-3: Inter-Reader Agreement for Modic Endplate Changes (MEPC) in the Lumbar Spine using the Dixon Protocol**

		Modic 1	Modic 1 and 2	Modic 2	Modic 3	No	Total	Cohen's Kappa	Standard Error	P-value
Dixon Protocol Reader 1: MEPC, L1-L2										
Dixon Protocol Reader 2: MEPC, L1-L2	No		1	0		135	136	0.845	0.054	<.001
	Modic 2	-	0	19	-	1	20			
	Modic 1 and 2		2	3		2	7			
Dixon Protocol Reader 1: MEPC, L2-L3										
Dixon Protocol Reader 2: MEPC, L2-L3	No	0	0	0		135	135	0.854	0.048	<.001
	Modic 2	2	1	17		0	20			
	Modic 1	2	1	2	-	1	6			
	Modic1 and 2	0	2	0		0	2			
Dixon Protocol Reader 1: MEPC, L3-L4										
Dixon Protocol Reader 2: MEPC, L3-L4	No	0	0	0		132	132	0.863	0.047	<.001
	Modic 2	2	1	20		1	24			
	Modic 1	2	0	2	-	0	4			
	Modic1 and 2	0	2	0		1	3			
Dixon Protocol Reader 1: MEPC, L4-L5										
Dixon Protocol Reader 2: MEPC, L4-L5	No	0	0	3	2	108	113	0.863	0.041	<.001
	Modic 2	0	0	41	0	2	43			
	Modic1 and 2	0	2	0	0	2	4			
	Modic 1	1	0	0	0	0	1			
	Modic 3	0	0	0	1	1	2			
Dixon Protocol Reader 1: MEPC, L5-S1										
Dixon Protocol Reader 2: MEPC, L5-S1	Modic 1	3	0	0	0	0	3	0.864	0.04	<.001
	Modic 1 and 2	0	3	0	0	1	4			
	Modic 2	0	0	60	0	3	63			
S1	Modic 3	0	0	0	1	2	3			
	No	0	1	4	1	84	90			

MEPC: Modic end plate changes, L1-L2: lumbar vertebra 1 and 2, L2-L3: lumbar vertebra 2 and 3, L3-L4: lumbar vertebra 3 and 4, L4-L5: lumbar vertebra 4 and 5, L5-S1: lumbar vertebra 5 and sacral vertebra 1

**Table-4: Inter-Reader Agreement for High-Intensity Zones (HIZ) in the Lumbar Spine using the Standard Protocol**

		No	Yes	Total	Cohen's Kappa	Standard Error	P-value
Standard Protocol Reader 1: HIZ L1-L2							
Standard Protocol Reader 2: HIZ L1-L2	No	158	1	159	0.866	0.113	<.001
	Yes	0	4	4			
Standard Protocol Reader 1: HIZ L2-L3							
Standard Protocol Reader 2: HIZ L2-L3	Yes	8	2	10	0.832	0.095	<.001
	No	1	152	153			
Standard Protocol Reader 1: HIZ L3-L4							
Standard Protocol Reader 2: HIZ L3-L4	Yes	23	0	23	0.863	0.054	<.001
	No	6	134	140			
Standard Protocol Reader 1: HIZ L4-L5							
Standard Protocol Reader 2: HIZ L4-L5	Yes	68	0	68	0.82	0.04	<.001
	No	15	80	95			
Standard Protocol Reader 1: HIZ L5-S1							
Standard Protocol Reader 2: HIZ L5-S1	Yes	64	6	70	0.84	0.04	<.001
	No	7	86	93			

HIZ: high intensity zone, L1-L2: lumbar vertebra 1 and 2, L2-L3: lumbar vertebra 2 and 3, L3-L4: lumbar vertebra 3 and 4, L4-L5: lumbar vertebra 4 and 5, L5-S1: lumbar vertebra 5 and sacral vertebra 1.

Intervertebral disc bulges and herniation causing nerve root compression and spinal canal stenosis are part of degenerative changes and assessed on axial sequences.<sup>27,28</sup> As axial sequences were not replaced in our study so there would be no loss of diagnostic information by substitution of the three routinely used sagittal sequences with the single T2 Dixon sequence.

**Conclusion**

Our study has proved that a single sagittal T2 Dixon sequence could replace the standard sagittal sequences for the assessment of MEPC and HIZs with a 30% acquisition time reduction at 1.5T.

**Acknowledgment:** None.

**Conflict of Interest:** The authors declare no conflict of interest.

**Grand Support and Financial Disclosure:** None.

**REFERENCES**

1. Anjum H, Khan MR, Naveed H, Iftikhar S, Imdad H. The relationship of age and gender with lumbar spine degenerative changes in patients with low back pain. Khyber Journal of Medical Sciences. 2024; 17: 6-16.

2. Albazli K, Alotaibi M, Almoallim H. Low-Back Pain. In: Almoallim H, Cheikh M, editors. Skills in Rheumatology. Singapore: Springer; 2021. p. 127-38.
3. Dydyk AM, Khan MZ, Singh P. Radicular Back Pain. [updated 2022 Oct 24]. In: StatPearls [Internet]. Treasure Island (FL): StatPearls Publishing; 2024 Jan-. Available from: <https://www.ncbi.nlm.nih.gov/books/NBK546593>
4. van der Graaf JW, Kroeze RJ, Buckens CF, Lessmann N, van Hooff ML. MRI image features with an evident relation to low back pain: a narrative review. European Spine Journal. 2023; 32: 1830-41. doi: 10.1007/s00586-023-07602-x
5. Donnally III CJ, Hanna A, Varacallo M. Lumbar Degenerative Disk Disease. [updated 2023 Aug 4]. In: StatPearls [Internet]. Treasure Island (FL): StatPearls Publishing; 2024 Jan-. Available from: <https://www.ncbi.nlm.nih.gov/books/NBK448134/>
6. Di Muzio B, Knipe H, Goel A. MRI classification system for lumbar disc degeneration. Radiopaedia.org. [cited 2024 Apr 13]. Available from: <https://doi.org/10.53347/rID-27904>
7. Oh CH, Yoon SH. Whole Spine Disc Degeneration Survey according to the Ages and Sex Using Pfirrmann Disc Degeneration Grades. Korean Journal of Spine. 2017; 14:

- 148-54. doi: 10.14245/kjs.2017.14.4.148
8. Teraguchi M, Cheung JPY, Karppinen J, Bow C, Hashizume H, Luk KDK, et al. Lumbar high-intensity zones on MRI: imaging biomarkers for severe, prolonged low back pain and sciatica in a population-based cohort. *The Spine Journal*. 2020; 20: 1025-34. doi: 10.1016/j.spinee.2020.02.015
  9. Radswiki T, Bell D, Veiga. Modic type endplate changes. *Radiopaedia.org*. [cited 2024 Apr 13]. Available from: <https://doi.org/10.53347/rID-12146>
  10. Czaplewski LG, Rimmer O, McHale D, Laslett M. Modic changes as seen on MRI are associated with nonspecific chronic lower back pain and disability. *Journal of Orthopaedic Surgery and Research*. 2023; 18: 351. doi: 10.1186/s13018-023-03839-w
  11. Zerunian M, Pucciarelli F, Caruso D, De Santis D, Polici M, Masci B, et al. Fast high- quality MRI protocol of the lumbar spine with deep learning-based algorithm: an image quality and scanning time comparison with standard protocol. *Skeletal Radiology*. 2024; 53: 151–9. doi: 10.1007/s00256-023-04390-9
  12. Finkenstaedt T, Del Grande F, Bolog N, Ulrich N, Tok S, Kolokythas O, et al. Modic Type 1 Changes: Detection Performance of Fat-Suppressed Fluid-Sensitive MRI Sequences. *RoFo*. 2018; 190: 152-60. doi: 10.1055/s-0043-118130
  13. Vargas MI, Boto J, Meling TR. Imaging of the spine and spinal cord: An overview of magnetic resonance imaging (MRI) techniques. *Revue Neurologique*. 2021; 177: 451-8. doi: 10.1016/j.neurol.2020.07.005
  14. Sollmann N, Fields AJ, O'Neill C, Nardo L, Majumdar S, Chin CT, et al. Magnetic resonance imaging of the lumbar spine: Recommendations for acquisition and image evaluation from the BACPAC spine imaging working group. *Pain Medicine*. 2023; 24: S81-94. doi: 10.1093/pm/pnac130
  15. Saifuddin A, Rajakulasingam R, Santiago R, Siddiqui M, Khoo M, Pressney I. Comparison of lumbar degenerative disc disease using conventional fast spin echo T<sub>2</sub>W MRI and T<sub>2</sub> fast spin echo dixon sequences. *The British Journal of Radiology*. 2021; 94: 20201438. doi: 10.1259/bjr.20201438
  16. Zanchi F, Richard R, Hussami M, Monier A, Knebel JF, Omoumi P. MRI of non-specific low back pain and/or lumbar radiculopathy: do we need T1 when using a sagittal T2-weighted Dixon sequence? *European Radiology*. 2020; 30: 2583-93. doi: 10.1007/s00330-019-06626-6
  17. Yang S, Lassalle L, Mekki A, Appert G, Rannou F, Nguyen C, et al. Can T2-weighted Dixon fat-only images replace T1-weighted images in degenerative disc disease with Modic changes on lumbar spine MRI? *European Radiology*. 2021; 31: 9380-9. doi: 10.1007/s00330-021-07946-2
  18. Maeder Y, Dunet V, Richard R, Becce F, Omoumi P. Bone Marrow Metastases: T2- weighted Dixon Spin-Echo Fat Images Can Replace T1-weighted Spin-Echo Images. *Radiology*. 2018; 286: 948-59. doi: 10.1148/radiol.2017170325
  19. Chen Y, Bao J, Yan Q, Wu C, Yang H, Zou J. Distribution of Modic changes in patients with low back pain and its related factors. *European journal of medical research*. 2019; 24: 34. doi: 10.1186/s40001-019-0393-6
  20. Teraguchi M, Cheung JPY, Karppinen J, Bow C, Hashizume H, Luk KDK, et al. Lumbar high-intensity zones on MRI: imaging biomarkers for severe, prolonged low back pain and sciatica in a population-based cohort. *The spine Journal: official journal of the North American Spine Society*. 2020; 20: 1025-34. doi: 10.1016/j.spinee.2020.02.015
  21. Waldenberg C, Eriksson S, Brisby H, Hebelka H, Lagerstrand KM. Detection of Imperceptible Intervertebral Disc Fissures in Conventional MRI-An AI Strategy for Improved Diagnostics. *Journal of clinical medicine*. 2022; 12: 11. doi: 10.3390/jcm12010011
  22. Teraguchi M, Hashizume H, Oka H, Cheung JPY, Samartzis D, Tamai H, et al. Detailed Subphenotyping of Lumbar Modic Changes and Their Association with Low Back Pain in a Large Population-Based Study: The Wakayama Spine Study. *Pain and therapy*. 2022; 11: 57-71. doi: 10.1007/s40122-021-00337-x.
  23. Huang H, Zhang Y, Zhang H, Chen J, Zheng Q, Cao D, et al. Qualitative and quantitative assessment of sacroiliitis in axial spondyloarthritis: can a single T2-weighted Dixon sequence replace the standard protocol? *Clinical Radiology*. 2020; 75: 321.e13- 321.e20. doi: 10.1016/j.crad.2019.12.011
  24. Allam MF, Isaac KR, Ismail AH, Ragaee SM. The value of chemical shift imaging and T1-Dixon MRI in evaluation of structural changes in sacroiliac joint in ankylosing spondylitis. *Egyptian Journal of Radiology and Nuclear Medicine*. 2022; 53: 127. doi: 10.1186/s43055-022-00800-5
  25. Athira R, Cannane S, Thushara R, Poyyamoli S, Nedunchelian M. Diagnostic Accuracy of Standalone T2 Dixon Sequence Compared with Conventional MRI in Sacroiliitis. *The Indian journal of radiology imaging*. 2022; 32: 314-23. doi: 10.1055/s-0042-1753467
  26. Sasiponganan C, Yan K, Pezeshk P, Xi Y, Chhabra A. Advanced MR imaging of bone marrow: quantification of signal alterations on T1-weighted Dixon and T2-weighted Dixon



- sequences in red marrow, yellow marrow, and pathologic marrow lesions. *Skeletal radiology*. 2020; 49: 541-8. doi: 10.1007/s00256-019-03303-z
27. Ko YJ, Lee E, Lee JW, Park CY, Cho J, Kang Y, et al. Clinical validity of two different grading systems for lumbar central canal stenosis: Schizas and Lee classification systems. *PLoS One*. 2020; 15: e0233633. doi: 10.1371/journal.pone.0233633
28. Elfadle AA, Zarad CA, Elmaaty AA, El-Nagaa BF, Soliman AY. Correlation between lumbar spinal canal magnetic resonance imaging grading systems and parameters in lumbar spinal canal compromise. *The Egyptian Journal of Neurology, Psychiatry and Neurosurgery*. 2022; 58: 104. doi: 10.1186/s41983-022-00543-0

#### Authors Contribution

**SJ:** Idea conception, study designing, data collection, data analysis, results and interpretation, manuscript writing and proofreading

**M:** Idea conception, study designing, data collection

**MI:** Data analysis, results and interpretation, manuscript writing and proofreading

**NG:** Data collection, manuscript writing and proofreading

**FJ:** Data collection, data analysis, results and interpretation, manuscript writing and proofreading

**AA:** Data collection, data analysis, results and interpretation, manuscript writing and proofreading

.....