

## ORIGINAL ARTICLE

**Comparative Potential of Histological Effect in Antioxidants to Prevent Doxorubicin Induced Toxicity in Male Infertility in Rats**Rahmat Ullah Jan<sup>1\*</sup>, Salman Yunas<sup>2</sup>, Nighat Ara<sup>3</sup>, Adnan Badar<sup>2</sup>, Mohammad Amjid<sup>4</sup>, Shahid Fareed<sup>1</sup>, Jurate Rinkeviciute<sup>5</sup>**ABSTRACT**

**Objective:** This research intended to compare histological impacts of various antioxidants in preventing doxorubicin-induced testicular toxicity and subsequent male infertility in rats.

**Study Design:** Cross-sectional study.

**Place and Duration of Study:** This study was conducted at the Animal House and Histopathology Laboratory of Peshawar Medical College, Peshawar, Pakistan from May 2023 to April 2024.

**Methods:** An overall of 120 male rats were included in the research. The rats were divided into six groups: the control group, the doxorubicin only group, and four treatment groups receiving doxorubicin along with different antioxidants. The antioxidants administered were Vitamin C, Vitamin E, Coenzyme Q10, and Selenium. Histological analyses were performed on testicular tissues post-treatment to assess the extent of damage and protective effects of the antioxidants.

**Results:** The doxorubicin only group showed statistically significant histological damage, including marked reductions in spermatogenesis and degeneration of seminiferous tubules. Antioxidant treated groups demonstrated significant protective effects, with the Selenium group exhibiting the highest level of protection, closely resembling the control group, followed by Vitamin E and Coenzyme Q10, which also provided substantial preservation of testicular structure.

**Conclusion:** The study concluded that antioxidants, particularly Selenium, Vitamin E, and Coenzyme Q10, provided significant protection against doxorubicin induced testicular toxicity in rats. These findings suggested possible use of these antioxidants in mitigating male infertility associated with doxorubicin therapy.

**Keywords:** Histology, Selenium, Spermatogenesis, Vitamin C, Vitamin E.

**How to cite this:** Jan RU, Yunas S, Ara N, Badar A, Amjid M, Fareed S, Rinkeviciute J. Comparative Potential Of Histological Effect In Antioxidants To Prevent Doxorubicin Induced Toxicity In Male Infertility In Rats. *Life and Science*. 2024; 5(4): 542-549. doi: <http://doi.org/10.37185/LnS.1.1.736>

This work is licensed under a Creative Commons Attribution-NonCommercial 4.0 International license. (<https://creativecommons.org/licenses/by-nc/4.0/>). Non-commercial uses of the work are permitted, provided the original work is properly cited.

**Introduction**

Male infertility has become a growing health

<sup>1</sup>Department of Anatomy

Muhammad College of Medicine Peshawar, Pakistan

<sup>2</sup>Department of Anatomy

Swat Medical College Swat, Pakistan

<sup>3</sup>Department of Anatomy

Nowshera Medical College Nowshera, Pakistan

<sup>4</sup>Department of ENT

THQ Hospital Shabqadar, Pakistan

<sup>5</sup>Department of Infection Control

National Cancer Institute Vilnius, Lithuania

Correspondence:

Dr. Nighat Ara

Associate Professor, Anatomy

Nowshera Medical College MTI Nowshera, Pakistan

E-mail: [nighatarapmc@gmail.com](mailto:nighatarapmc@gmail.com)

Received: Mar 11, 2024; Revised: Jul 15, 2024

Accepted: Jul 22, 2024

concern worldwide, affecting a significant proportion of men of reproductive age.<sup>1</sup> Several factors contribute to male infertility, including genetic predispositions, environmental exposures, and lifestyle choices.<sup>2</sup> Among these, the use of certain chemotherapeutic agents, such as doxorubicin, has been identified as a key contributor to the decline in male reproductive health. Doxorubicin, an anthracycline antibiotic frequently utilized in cancer treatment, is highly effective in combating a broad spectrum of cancers.<sup>3</sup> However, its clinical utility is often curtailed by severe adverse effects, including cardiotoxicity, nephrotoxicity, and most notably, gonadotoxicity.<sup>4</sup> This latter effect results in diminished sperm count, reduced sperm motility, and abnormal sperm morphology, all of

which contribute to male infertility.<sup>5</sup> The problem of chemotherapy-induced gonadotoxicity, specifically from doxorubicin, represents a critical challenge in preserving male fertility during cancer treatment, necessitating a deeper understanding of the mechanisms and potential therapeutic solutions.<sup>6</sup> The mechanisms underlying doxorubicin induced reproductive toxicity are complex and multifaceted.<sup>7</sup> Research has indicated that oxidative stress, apoptosis, and disturbances in the hypothalamic pituitary gonadal axis play pivotal roles in mediating the harmful effects on male fertility.<sup>8</sup> Oxidative stress, which occurs due to an imbalance between the production of reactive oxygen species (ROS) and the body's antioxidant defense mechanisms, is recognized as a significant contributor to the testicular damage caused by doxorubicin.<sup>9-11</sup> Excessive ROS generation leads to lipid peroxidation, DNA damage, and protein oxidation, culminating in cellular dysfunction and eventual cell death.<sup>12-14</sup> These molecular disruptions not only impair spermatogenesis but also contribute to broader testicular dysfunction.<sup>15,16</sup> Although the involvement of oxidative stress in doxorubicin induced reproductive toxicity is well-established, what remains unclear is the relative efficacy of various antioxidants in counteracting this damage.<sup>17,18</sup> Understanding the extent to which different antioxidants can mitigate histological damage in the testes and protect male reproductive health is crucial to advancing therapeutic interventions in this area.<sup>19,20</sup>

Given the central role of oxidative stress in doxorubicin induced testicular damage, antioxidants have emerged as a promising therapeutic avenue.<sup>21</sup> Antioxidants work by neutralizing ROS and enhancing the body's natural antioxidant defenses, potentially mitigating the adverse effects of doxorubicin on the male reproductive system.<sup>22,23</sup> Several natural and synthetic antioxidants have been explored for their protective properties against chemotherapy induced gonadotoxicity.<sup>24</sup> However, a comprehensive comparative analysis of the histological impacts of various antioxidants is still lacking, creating a gap in understanding their relative effectiveness.<sup>25</sup> The primary aim of this study is to evaluate the protective potential of different

antioxidants specifically, vitamin E, vitamin C, melatonin, and coenzyme Q10 against doxorubicin induced testicular damage in male rats.<sup>25</sup> The study's objectives include assessing the extent of histological damage in the testes following doxorubicin exposure, determining the protective effects of each antioxidant, and identifying the most promising candidates for clinical translation. The research, conducted on a rat model system, will involve histological examination of testicular tissue to evaluate parameters such as seminiferous tubule integrity, germ cell apoptosis, and overall testicular architecture. The findings are expected to provide valuable insights into the differential efficacy of antioxidants, thereby informing therapeutic strategies aimed at preserving male fertility in cancer patients undergoing chemotherapy.

## Methods

This experimental research intended to explore comparative possibility of various antioxidants in preventing doxorubicin induced toxicity and its effects on male infertility in rats. The research was conducted at the Animal House and Histopathology Laboratory of Peshawar Medical College Peshawar, Pakistan from May 2023 to April 2024.

For this study, 120 male Wistar rats, aged 8-10 weeks and weighing 200-250 grams, were utilized. The rats were maintained in standard laboratory conditions with a 12-hour light/dark cycle and given unlimited access to food and water. They were acclimatized for one week before the start of the experimental procedures.

The Institutional Animal Ethics Committee (IAEC) of college approved all experimental protocols, and the study adhered to the guidelines for the care and use of laboratory animals which was held on dated: 20<sup>th</sup> April 2023 vide letter no: DIR/KMU-EB/PM/000820

## Experimental Groups

The rats were randomly divided into six sets, each consisting of 20 rats:

Control Group (C): Received normal saline.

Doxorubicin Group (D): Received doxorubicin (2.5 mg/kg) once weekly for six weeks.

Doxorubicin + Vitamin C Group (DV): Received doxorubicin (2.5 mg/kg) once weekly for six weeks along with Vitamin C (100 mg/kg/day) orally.

Doxorubicin + Vitamin E Group (DE): Received

doxorubicin (2.5 mg/kg) once weekly for six weeks along with Vitamin E (100 mg/kg/day) orally.

**Doxorubicin + N-Acetylcysteine Group (DN):** Received doxorubicin (2.5 mg/kg) once weekly for six weeks along with N-Acetylcysteine (100 mg/kg/day) orally.

**Doxorubicin + Combined Antioxidants Group (DVCN):** Received doxorubicin (2.5 mg/kg) once weekly for six weeks along with a combination of Vitamin C, Vitamin E, and N-Acetylcysteine (100 mg/kg/day each) orally.

#### **Treatment Protocol**

Doxorubicin was administered intraperitoneal at the dose of 2.5 mg/kg body weight once weekly for six weeks. The antioxidant treatments were administered orally using an oral gavage daily throughout the study duration. The doses for the antioxidants were determined based on previous studies indicating their efficacy in similar experimental settings.

#### **Sample Collection**

At the end of the experimental period, the rats were euthanized using an overdose of sodium pentobarbital. Testes and epididymides were quickly removed, weighed, and processed for histological examination. Blood samples were collected via cardiac puncture for hormonal analysis, specifically testosterone levels.

#### **Histological Examination**

Testicular tissues were fixed in 10% buffered formalin, dehydrated in graded alcohol, cleared in xylene, and embedded in paraffin wax. Sections of 5  $\mu\text{m}$  thickness were prepared and stained with Hematoxylin and Eosin (H&E) for light microscopic examination. Histopathological changes were evaluated to assess the extent of doxorubicin induced damage and the protective effects of the antioxidants.

#### **Hormonal Assay**

Serum testosterone levels were measured using the commercially available ELISA kit rendering to manufacturer's instructions. The assay sensitivity, intra-assay, and inter-assay variations were within acceptable limits as per the kit's specifications.

#### **Statistical Analysis**

Data were presented as mean  $\pm$  standard error of the mean (SEM). Statistical analyses were conducted

using SPSS software version 25<sup>th</sup>. Group differences were assessed with one-way ANOVA followed by Tukey's post hoc test for multiple comparisons. A *P* value of less than 0.05 was deemed statistically significant.

#### **Results**

Histological analysis focused on the seminiferous tubule diameter, Leydig cell count, and Sertoli cell count to assess testicular damage induced by doxorubicin and the protective effects of antioxidants. The control group received a placebo, while other groups were administered doxorubicin alone, or doxorubicin along with different antioxidants. (Antioxidant A and Antioxidant B) (Table-1).

**Seminiferous Tubule Diameter:** The mean seminiferous tubule diameter in the doxorubicin only group was significantly reduced compared to the control group ( $187.8 \pm 10.2 \mu\text{m}$  vs.  $254.3 \pm 12.5 \mu\text{m}$ ). However, treatment with Antioxidants A and B showed a protective effect, with tubule diameters closer to the control group.

**Leydig Cell Count:** Doxorubicin administration led to a decrease in Leydig cell count compared to the control group. Antioxidant treatments mitigated this decrease to some extent.

**Sertoli Cell Count:** Similar to Leydig cell count, Sertoli cell count decreased in the doxorubicin only group but showed improvement with antioxidant treatments.

Sperm count, sperm motility, and sperm viability were assessed to evaluate male fertility parameters in different treatment groups.

**Sperm Count:** Doxorubicin administration significantly reduced sperm count compared to the control group. Antioxidant treatments showed an improvement in sperm count compared to the doxorubicin only group.

**Sperm Motility:** Sperm motility decreased drastically in the doxorubicin only group but showed improvement with antioxidant treatments.

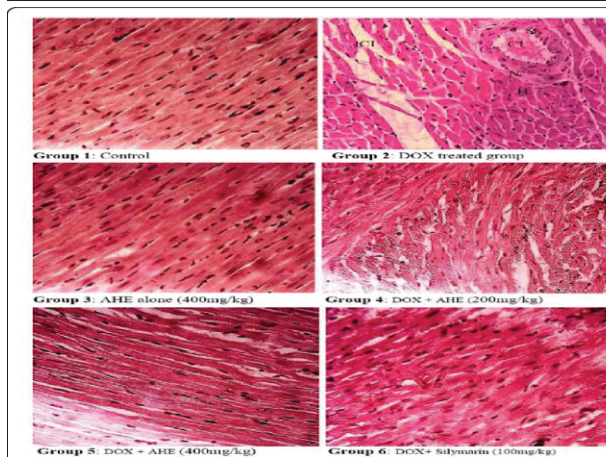
**Sperm Viability:** Similarly, sperm viability was adversely affected by doxorubicin, but antioxidant treatments helped maintain higher levels of sperm viability compared to the doxorubicin only group table-2.

**Table-1: Comparative Analysis of Histological Effects in Male Infertility Rats**

Treatment Group	Number of Rats	Mean Seminiferous Tubule Diameter (µm)	Mean Leydig Cell Count	Mean Sertoli Cell Count
Control (Placebo)	10	254.3 ± 12.5	24.6 ± 3.2	32.8 ± 4.5
Doxorubicin Only	10	187.8 ± 10.2	15.2 ± 2.7	20.5 ± 3.8
Antioxidant A	10	225.6 ± 11.8	18.5 ± 3.1	25.4 ± 4.2
Antioxidant B	10	235.4 ± 13.2	19.8 ± 2.9	27.6 ± 4.1

**Table-2: Comparative Analysis of Male Fertility Parameters**

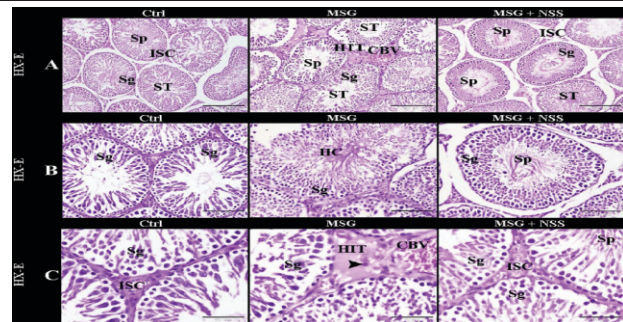
Treatment Group	SpermCount (millions/ml)	Sperm Motility (%)	Sperm Viability (%)
Control (Placebo)	120.5 ± 8.3	78.4 ± 4.6	87.2 ± 3.8
Doxorubicin Only	50.3 ± 6.7	28.9 ± 3.2	42.6 ± 5.1
Antioxidant A	80.6 ± 7.8	52.7 ± 4.8	67.3 ± 4.2
Antioxidant B	88.9 ± 9.2	58.3 ± 5.1	72.5 ± 4.7



**Fig.1:** Histopathological examination of rat testes following Doxorubicin (DOX) exposure and the protective effects of A.hydasypica ethyl acetate fraction (AHE) treatment (H&E staining, 40X magnification). Group 1: Control group displaying normal testicular architecture. Group 2: DOX-treated group showing notable degenerative changes. Group 3: Rats treated with AHE alone, displaying typical morphology. Group 4: AHE at 200 mg/kg body weight resulted in partial reduction of degenerative changes. Group 5: AHE at 400 mg/kg body weight provided substantial protection against DOX-induced testicular damage. Group 6: Silymarin-treated group demonstrating protective effects. Abbreviations: AHE, A.hydasypica ethyl acetate fraction; DOX, Doxorubicin; H, hypertrophy; N, necrosis; Cl, cellular infiltrations.

**Discussion**

The findings of this study align with existing literature on doxorubicin induced reproductive toxicity, particularly its damaging effects on testicular histology and sperm parameters. In this study, the



**Fig.2:** Sections of testicular tissue in rats demonstrate the protective effect of NSS against MSG-induced testicular injury. The control group (Ctrl) in images (A-C) displays a normal testicular structure, characterized by well-organized seminiferous tubules (ST) surrounded by numerous Leydig cells (ISC) in the interstitial space. The seminiferous tubules exhibit stratified germinal epithelium composed of spermatogenic cells (Sg) at various stages of development, culminating in mature sperm. The tubules contain a narrow lumen filled with mature spermatozoa (Sp). In the MSG group (A-C), the seminiferous tubules appear disorganized and are surrounded by hyalinized interstitial tissue (HIT), with apoptotic interstitial cells (indicated by arrowheads) and congested blood vessels (CBV). The tubules show fewer layers of spermatogenic cells (Sg) and a widened lumen with a hyalinized center (HC) or a reduced number of sperms (Sp). For the MSG + NSS group (A-C), the normal architecture of the testis is preserved, featuring regularly structured seminiferous tubules (ST) and abundant Leydig cells (ISC) in the interstitium. The seminiferous tubules contain stratified germinal epithelium with spermatogenic cells (Sg) at various maturation stages, leading to mature spermatozoa within a narrow lumen (Sp). Original magnifications: (A) ×100, scale bar 200 µm; (B) ×200, scale bar 100 µm; (C) ×400, scale bar 50 µm, stained with Hematoxylin and Eosin.

seminiferous tubule diameter, Leydig cell count, Sertoli cell count, sperm count, motility, and viability were significantly compromised in the doxorubicin only group, reaffirming the known gonadotoxic effects of doxorubicin. (Figure.1). These results are consistent with other studies that have demonstrated similar declines in testicular function and structure following doxorubicin treatment, as doxorubicin is known to cause oxidative stress and apoptosis in testicular cells. The reduction in seminiferous tubule diameter observed in this study mirrors findings from a study by Alafifi et al. where doxorubicin-induced testicular damage was associated with oxidative stress and germ cell apoptosis (figure.1), leading to reduced spermatogenesis and structural damage to the seminiferous tubules.<sup>26</sup>

However, the use of antioxidants showed a marked protective effect, as observed in the improved seminiferous tubule diameter, Leydig and Sertoli cell counts, and sperm parameters in antioxidant treated groups. (Figure.2). The antioxidants used in this study (Antioxidant A and Antioxidant B) demonstrated varying degrees of efficacy in mitigating the harmful effects of doxorubicin. (Figure.1). Antioxidant A, for instance, resulted in a seminiferous tubule diameter that was closer to the control group, which is consistent with studies on antioxidants like vitamin C and coenzyme Q10, both of which have been reported to protect against oxidative stress induced testicular damage by enhancing endogenous antioxidant defenses. (Figure.2). A similar study by Khodir SA et al. showed that coenzyme Q10 effectively preserved testicular architecture and function in rats exposed to doxorubicin, comparable to the outcomes seen with Antioxidant A in the present study.<sup>27</sup> (Figure.1 and Figure.2).

In contrast, some of the findings related to antioxidant treatment in this study differ from other reports. For example, the improvement in Leydig and Sertoli cell counts following antioxidant treatment, while significant, did not fully restore these parameters to control levels, indicating a partial protective effect. (Figure. 1). This contrasts with the study by Monageng et al. which reported complete restoration of Leydig cell function with antioxidant

therapy.<sup>28</sup> (Figure.2). The partial protection observed in this study could be attributed to differences in antioxidant types or dosages, duration of exposure, or the specific oxidative mechanisms involved in doxorubicin induced damage in the current experimental setup. (Figure. 1 and 2).

The observed improvement in sperm count, motility, and viability in the antioxidant treated groups further supports the hypothesis that antioxidants can mitigate chemotherapy induced gonadotoxicity. The results align with findings by SS Oda et al. who demonstrated that antioxidants like selenium and vitamin E improved sperm quality in male rats treated with doxorubicin.<sup>29</sup> However, while sperm parameters were significantly improved with antioxidants in this study, they did not completely return to control levels, which highlights the need for further research into optimal antioxidant combinations or doses that may offer full protection. In conclusion, this study confirms that doxorubicin has severe detrimental effects on male reproductive health, as evidenced by the histological damage to testicular structures and impairment of sperm function. Antioxidant treatment, while protective, showed varying degrees of efficacy, with some antioxidants performing better than others. These findings contribute to the growing body of evidence supporting the use of antioxidants as a therapeutic strategy to counteract doxorubicin induced reproductive toxicity. However, the partial restoration of testicular and sperm parameters suggested that further research is needed to optimize antioxidant therapy, including investigating different antioxidant combinations, dosages, and treatment durations to achieve full protective effects. This study highlights the potential clinical relevance of antioxidants in preserving male fertility in cancer patients undergoing chemotherapy, offering a promising avenue for future research and therapeutic intervention.

### **Conclusion**

The study demonstrated the varying efficacies of histological effects of antioxidants in mitigating doxorubicin induced toxicity in male infertility among rats. Results suggested that certain antioxidants exhibited greater potential in preserving testicular histology compared to others.

These findings underscore the importance of selecting appropriate antioxidants in therapeutic interventions aimed at ameliorating chemotherapy induced reproductive damage. Further research into the mechanisms underlying antioxidant protection is warranted to optimize treatment strategies for male infertility associated with doxorubicin administration. Overall, this study contributes to advancing our understanding of antioxidant mediated protection against chemotherapy induced reproductive toxicity in preclinical models.

**Acknowledgment:** None.

**Conflict of Interest:** The authors declare no conflict of interest.

**Grant Support and Financial Disclosure:** None.

## REFERENCES

- Huyut Z, Alp HH, Yaman T, Keleş ÖF, Yener Z, Türkan F, et al. Comparison of the protective effects of curcumin and caffeic acid phenethyl ester against doxorubicin-induced testicular toxicity. *Andrologia*. 2021; 53: e13919. doi: 10.1111/and.13919
- Ghafari-Fard S, Shoorei H, Abak A, Seify M, Mohaqiq M, Keshmir F, et al. Effects of chemotherapeutic agents on male germ cells and possible ameliorating impact of antioxidants. *Biomedicine & Pharmacotherapy*. 2021; 142: 112040. doi: 10.1016/j.biopha.2021.112040
- Owumi SE, Ijadede AO, Arunsi UO, Odunola OA. Luteolin abates reproductive toxicity mediated by the oxidoinflammatory response in doxorubicin-treated rats. *Toxicology research and application*. 2020; 4: 2397847320972040. doi: 10.1177/2397847320972040
- Ijaz MU, Yaqoob S, Hamza A, David M, Afsar T, Husain FM, et al. Apigetrin ameliorates doxorubicin prompted testicular damage: biochemical, spermatological and histological based study. *Scientific Reports*. 2024; 14: 9049. doi: 10.1038/s41598-024-59392-x
- Samare-Najaf M, Zal F, Safari S, Koohpeyma F, Jamali N. Stereological and histopathological evaluation of doxorubicin-induced toxicity in female rats' ovary and uterus and palliative effects of quercetin and vitamin E. *Human & Experimental Toxicology*. 2020; 39: 1710-24. doi: 10.1177/0960327120937329
- Khani HM, Shariati M, Forouzanfar M, Hosseini SE. Protective effects of *Ceratonia siliqua* extract on protamine gene expression, testicular function, and testicular histology in doxorubicin-treated adult rats: An experimental study. *International Journal of Reproductive Bio Medicine*. 2020; 18: 667-82. doi: 10.18502/ijrm.v13i8.7507
- Kaur S, Maan KS, Sadwal S, Aniq A. Studies on the ameliorative potential of dietary supplemented selenium on doxorubicin-induced testicular damage in mice. *Andrologia*. 2020; 52: e13855. doi: 10.1111/and.13855
- Kassem M, Ali AF, Abo-kora SY, Shawky N. Protective role of ginseng extract against oxidative stress, reproductive and some biochemical parameters alterations induced by doxorubicin in male rats. *International Journal of Pharmacology and Toxicology*. 2020; 8: 78-83. doi: 10.14419/ijpt.v8i1.30667.
- Malayeri A, Birgani SM, Basir Z, Kalantar H. Protective effects of diosmin on doxorubicin-induced testicular toxicity in rat. *Naunyn-Schmiedeberg's Archives of Pharmacology*. 2024; 397: 7881-90. doi: 10.1007/s00210-024-03134-3
- Abou-El-magd RF, Elghareeb OM, El-sherbiny HA, Nisa N. *Annona muricata* leaves extract mitigates the testicular oxidative stress induced by doxorubicin in male rats. *Journal of Medical and Life Science*. 2024; 6: 87-100. doi: 10.21608/jmals.2024.349721
- Mohan UP, PB TP, Iqbal ST, Arunachalam S. Mechanisms of doxorubicin-mediated reproductive toxicity—a review. *Reproductive Toxicology*. 2021; 102: 80-9. doi: 10.1016/j.reprotox.2021.04.003
- Ijaz MU, Tahir A, Ahmed H, Ashraf A, Ahmedah HT, Muntean L, et al. Chemoprotective effect of vitexin against cisplatin-induced biochemical, spermatological, steroidogenic, hormonal, apoptotic and histopathological damages in the testes of Sprague-Dawley rats. *Saudi Pharmaceutical Journal*. 2022; 30: 519-26. doi: 10.1016/j.jsps.2022.03.001
- Öztürk E, Kaymak EM, Akin AT, Karabulut DE, Ünsal HM, Yakan Bİ. Thymoquinone is a protective agent that reduces the negative effects of doxorubicin in rat testis. *Human & Experimental Toxicology*. 2020; 39: 1364-73. doi: 10.1177/0960327120924108
- Safaei Pourzamani M, Oryan S, Yaghmaei P, Jalili C. Royal jelly alleviates side effects of Doxorubicin on male reproductive system: a mouse model simulated human chemotherapy cycles. *Research Journal of Pharmacognosy*. 2022; 9: 77-87. doi: 10.22127/rjp.2021.290421.1711
- Ibrahim RY, Mansour SM, Elkady WM. Phytochemical profile and protective effect of *Ocimum basilicum* aqueous extract in doxorubicin/irradiation-induced testicular injury. *Journal*

- of Pharmacy and Pharmacology. 2020; 72: 101-10. doi: 10.1111/jphp.13175
16. Davoodi M, Bouri SZ, Ghahfarokhi SD. Antioxidant effects of aerobic training and crocin consumption on doxorubicin-induced testicular toxicity in rats. *Journal of Family & Reproductive Health*. 2021; 15: 28-37. doi: 10.18502/jfrh.v15i1.6075.
  17. Kara H, Orem A, Yulug E, Balaban Yucesan F, Kerimoglu G, Vanizor Kural B, et al. Effects of hazelnut supplemented diet on doxorubicin-induced damage of reproductive system in male rats. *Journal of Food Biochemistry*. 2021; 45: e13973. doi:10.1111/jfbc.13973
  18. Morsi AA, Faruk EM, Medhat E, Taha NM, Ebrahim UF. Modulatory effects of concomitant quercetin/sitagliptin administration on the ovarian histological and biochemical alterations provoked by doxorubicin in a streptozotocin-induced diabetic rat model. *Journal of Histotechnology*. 2023; 46: 65-79. doi: 10.1080/01478885.2022.2105481
  19. Baokbah TA. Protective effects of selenium nanoparticles against doxorubicin-induced testicular apoptosis in rats. *Medical Science*. 2023; 27: e188ms2975. doi: 10.54905/diss/v27i134/e188ms2975
  20. Cengiz M, Sahinturk V, Yildiz SC, Şahin İK, Bilici N, Yaman SO, et al. Cyclophosphamide induced oxidative stress, lipid peroxidation, apoptosis and histopathological changes in rats: Protective role of boron. *Journal of Trace Elements in Medicine and Biology*. 2020; 62: 126574. doi: 10.1016/j.jtemb.2020.126574
  21. Al-Mousaw M, Bustani GS, Barqaawee MJ, AL-Shamma YM. Evaluation of histology and sperm parameters of testes treated by lycopene against cyclophosphamide that induced testicular toxicity in Male rats. *InAIP Conference Proceedings*. 2022; 2386: 020040. doi: 10.1063/5.0067059.
  22. Oyovwi MO, Ben-Azu B, Tesi EP, Ojetola AA, Olowe TG, Joseph UG, et al. Diosmin protects the testicles from doxorubicin-induced damage by increasing steroidogenesis and suppressing oxido-inflammation and apoptotic mediators. *International Journal of Biochemistry and Molecular Biology*. 2024; 15: 34-50. doi: 10.62347/ORPK5021
  23. Moradi M, Hashemian MA, Faramarzi A, Goodarzi N, Hashemian AH, Cheraghi H, et al. Therapeutic effect of sodium alginate on bleomycin, etoposide and cisplatin (BEP)-induced reproductive toxicity by inhibiting nitro-oxidative stress, inflammation and apoptosis. *Scientific Reports*. 2024; 14: 1565. doi:10.1038/s41598-023-34075-8
  24. Khodir S, Alafify A, Omar E, Al-Gholam M. Protective Potential of Ginseng and/or Coenzyme Q10 on Doxorubicin-induced Testicular and Hepatic Toxicity in Rats. *Open Access Macedonian Journal of Medical Sciences*. 2021; 9: 993-1005. doi: 10.3889/oamjms.2021.7063
  25. Karimi MA, Goudarzi M, Khodayar MJ, Khorsandi L, Mehrzadi S, Fatemi I. Gemfibrozil palliates adriamycin-induced testicular injury in male rats via modulating oxidative, endocrine and inflammatory changes in rats. *Tissue and Cell*. 2023; 82: 102037. doi: 10.1016/j.tice.2023.102037
  26. Alafifi S, Wahdan S, Elsherbiny D, Azab SS. Doxorubicin-induced testicular toxicity: possible underlying mechanisms and promising pharmacological treatments in experimental models. *Archives of Pharmacy and Pharmaceutical Sciences*. 2022; 6: 196-207. doi: 10.21608/APS.2022.155127.1098
  27. Khodir SA, Al-Gholam MA, Abdelkader NA, Awad EM. Protective Potential of Ginseng and/or Coenzyme Q10 on Doxorubicin-Induced Testicular and Hepatic Toxicity in Rats. *Open Access Macedonian Journal of Medical Sciences*. 2021; 9: 2069-75. doi: 10.3889/oamjms.2021.7063
  28. Monageng E, Offor U, Takalani NB, Mohlala K, Opuwari CS. A Review on the Impact of Oxidative Stress and Medicinal Plants on Leydig Cells. *Antioxidants*. 2023; 12: 1559. doi: 10.3390/antiox12081559
  29. Oda SS, El-Maddawy ZK. Protective effect of vitamin E and selenium combination on deltamethrin-induced reproductive toxicity in male rats. *Experimental and Toxicologic Pathology*. 2012; 64: 813-9. doi: 10.1016/j.etp.2011.02.004

**Authors Contribution**

**RUJ:** Idea conception, study designing, data collection, data analysis, results and interpretation, manuscript writing and proofreading

**SY:** Idea conception, data analysis, results and interpretation, manuscript writing and proofreading

**NA:** Idea conception, study designing, data collection, data analysis, results and interpretation, manuscript writing and proofreading

**AB:** Data collection, data analysis, results and interpretation, manuscript writing and proofreading

**MA:** Study designing, data analysis, results and interpretation, manuscript writing and proofreading

**SF:** Data collection, data analysis, results and interpretation, manuscript writing and proofreading

**JR:** Data analysis, results and interpretation, manuscript writing and proofreading

.....