

ORIGINAL ARTICLE

Effectiveness of an Auto-stable Bicanaliculus Intubation Stent in the Management of Acquired Punctal StenosisMurtaza Sameen^{1*}, Muhammad Shahid², Muhammad Adnan¹, Rebecca³, Muhammad Teyyeb Azeem¹**ABSTRACT**

Objective: To determine the effectiveness of an autostable bicanaliculus Intubation stent in the management of acquired punctal stenosis in adults.

Study Design: Quasi-experimental study.

Place and Duration of Study: The study was carried at the Armed Forces Institute of Ophthalmology (AFIO), Rawalpindi, Pakistan, from April 2022 to November 2022.

Materials and Methods: A sum of 16 subjects were included in this study, of which 11 were females, and 4 were males, while one patient did not fulfill the follow-up criteria of our study, so was not included. In adult patients with proximal punctal stenosis, bicanalicular auto-stable self-retaining stents were implanted after performing probing sac syringing. Follow-up was done up to 06 months, and anatomical and functional success was determined with the help of munk score system of epiphora, which states 0 means no epiphora and 5 means constant epiphora.

Results: Out of 15 subjects, 11 (73.3%) were females, and 4 (26.7%) were males, who underwent bicanalicular stents. In 14 (93.3%) subjects, anatomical and functional success was noticed, while in one (6.7%) patient, extrusion of the tube occurred.

Conclusion: The treatment of proximal punctal stenosis in adults can be easily done with the help of bicanalicular auto-stable self-retaining stents which not only improve the anatomical success rate but also improves the functioning of the puncti.

Keywords: *Bicanalicular Auto-stable Self-retaining stents, Epiphora, Proximal Punctal Stenosis.*

How to cite this: Sameen M, Shahid M, Adnan M, Rebecca, Azeem MT. Effectiveness of an Autostable Bicanaliculus Intubation Stent in The Management of Acquired Punctal Stenosis. 2023; 4(3): 258-262. doi: <http://doi.org/10.37185/LnS.1.1.327>

This work is licensed under a Creative Commons Attribution-NonCommercial 4.0 International license.

(<https://creativecommons.org/licenses/by-nc/4.0/>). Non-commercial uses of the work are permitted, provided the original work is properly cited.

Introduction

Epiphora is commonly seen in patients with proximal punctal stenosis. Incidence of epiphora secondary to lacrimal system obstruction was seen to be about 11% at 50 years of age, whereas the ratio was increased to 30% at 80 years of age.¹ Another study from literature discusses the incidence of proximal punctal stenosis after age of 40 increases at a rate of

30.47 per 100,000 annually.¹ In view of the increased number of cases seen in clinical practice, it is much likely that actual number of patients with epiphora presented in literature could be much more higher. The frequency of patients with partial or functional lacrimal system obstruction is much more than the patients having complete nasolacrimal duct obstruction.^{1,2}

Two parts of the lacrimal system have been described: one is proximal and the other is distal. The proximal part consists of the punctum, canaliculi, and common canaliculus, while distal part comprises of the lacrimal sac and nasolacrimal duct, which drain tears into the inferior meatus. The punctum measures approximately 0.3mm in diameter and is almost 6.0mm (upper) and 6.5mm (lower) from the medial canthus. Various causes of proximal punctal occlusion have been discussed.^{1,2} Most common causes are posterior blepharitis, viral infections of eyelid margins, post-operative steroids use,

¹Department of Ophthalmology/Orbit and Oculoplastic²
Armed Forces Institute of Ophthalmology (AFIO),
Rawalpindi, Pakistan

³Department of Ophthalmology
Al-Shifa Trust Eye Hospital, Rawalpindi, Pakistan

Correspondence:

Dr. Murtaza Sameen

Specialist Registrar, Ophthalmology

Armed Forces Institute of Ophthalmology (AFIO),
Rawalpindi, Pakistan

E-mail: drmurtazasameen@gmail.com

Funding Source: NIL; Conflict of Interest: NIL

Received: Dec 09, 2022; Revised: Mar 07, 2023

Accepted: Apr 11, 2023

involutional, various topical drugs such as anti-glaucoma and cyclosporine, trauma, conjunctival and chemical burns. Proximal punctal stenosis and canalicular stenosis is one of the common causes of epiphora these days among patients presenting with watery eyes, usually, both eyes get involved simultaneously with variable severity.^{3,4} Thus for the treatment of proximal punctal stenosis, various different methods have been used. Of them the most commonly used methods are probing sac syringing, one-two- three snip procedures, kelley's punch punctoplasty, silicone tubes and autostable self-retaining stents. These bicanalicular autostable self-retaining stents are newly designed for proximal punctal and canalicular stenosis. Like other bicanalicular stents, these stents (nanchaku-style) allows tears to flow through the punctum by their wick system, which is not present in monocanalicular stents. These nanchaku-style stents consist of 2 silicon anchors connected to a silicone body, delivered pre-mounted on two guides and packaged with a disposable dilator. These tubes are available in three different sizes: 25mm, 30mm and 35mm. This procedure is easy and office based and can be performed under topical anaesthesia.^{1,4,5}

To the best of our knowledge no such study has been conducted in Pakistan. In this study, the effect of auto stable self-retaining stents have been determined in adult patients having proximal punctal stenosis with patent nasolacrimal duct.

Materials and Methods

This quasi-experimental study was carried out from April 2022 to November 2022 after approval from the hospital ethical review committee (278-a/ERC/AFIO). Sample size of 16 patients was estimated by 95% confidence interval, with the absolute perception of 5.5% with an open EPI info calculator.³

After informed written consent, both males and female above 50 years with acquired proximal punctal stenosis (grade 0-2 of the Kashkouli scale) having constant epiphora (Munk score 5) were included in this study.

Kashkouli scale

- 0- No punctum (agenesis)
- 1-Papilla is covered with a membrane
- 2- Less than normal size but recognizable

3- normal

4- Small slit (less than 2mm)

5- Large slit (less than or equal to 2mm)

The munk scale comprises of 0-5 grades

grade 0; no epiphora, grade 1; epiphora less than twice a day, grade 2; epiphora 2-4 times a day, grade 3; epiphora 5-10 times a day, grade 4; epiphora more than 10 times a day, grade 5; constant epiphora.

Those patients with intermittent epiphora, either secondary to trauma or secondary punctal stenosis and punctal stenosis of more than grade 1 and above according to the kashkouli scale, having a previous history of eyelid surgery and overlying lump over punctum were excluded from the study. After instillation of topical anaesthesia lignocaine 0.5 % eye drops, upper punctum was dilated firstly, followed by lower at a distance of 6.0mm and 6.5 mm approx: from medial can thus, probing (Bowman probe 00), and syringing was done. Patency of the nasolacrimal duct was seen with the help of irrigation with 2 ml of balanced saline solution through the punctum. Bicanalicular auto stable self-retaining stents (FCI 35mm) were implanted (figure 1). The stent comprises a mark in the center, which should lie ideally between the two puncti but mostly, it becomes hidden in common canaliculus. The stent was detached from the two nanchaku attached at the distal end of tube by slightly rotating it in anti-clockwise direction. Postoperatively topical antibiotic eye drops along with topical steroids eye drops were given four times a day for 7 days. Follow up was done at 1 day, 1 week, and 1 month for up to 06 months and anatomical and functional success was assessed in which the absence of epiphora was noticed with the Munk epiphora scale along with patency of punctum. Tubes were removed after 6 weeks postoperatively in absence of epiphora.

Statistical analysis was performed with SPSS version 22.0. confidence interval of 95% was used and a *p*-value of <0.05% was considered statistically significant.

Results

A total of fifteen patients were included in this study, 11(73.3%) females with bilateral proximal punctal stenosis and 4(26.7%) male with bilateral proximal punctal stenosis. One patient lost follow-up and was not included in this study. The total mean age of

patients was 58.80 ± 7.36 years in which the mean age of the male was 62.50 ± 5.9 years and that of the female was 57.45 ± 7.5 years (Table 1). Both the right and left eyes of all patients were included in this study.

In 14 (93.3%) patients, anatomical and functional success was noticed at the end of 06 months. Extrusion of tubes was seen in one (6.7%) patient, which occurred due to patient's own fingernail trauma.

Variables	Frequency n (%)
Age in years (MEAN \pm SD)	58.80 ± 7.36
Gender	
Male	04 (26.7%)
Female	11(73.3%)
Follow-up (06 months)	
Success	14 (93.3%)
Failure	01 (6.7%)

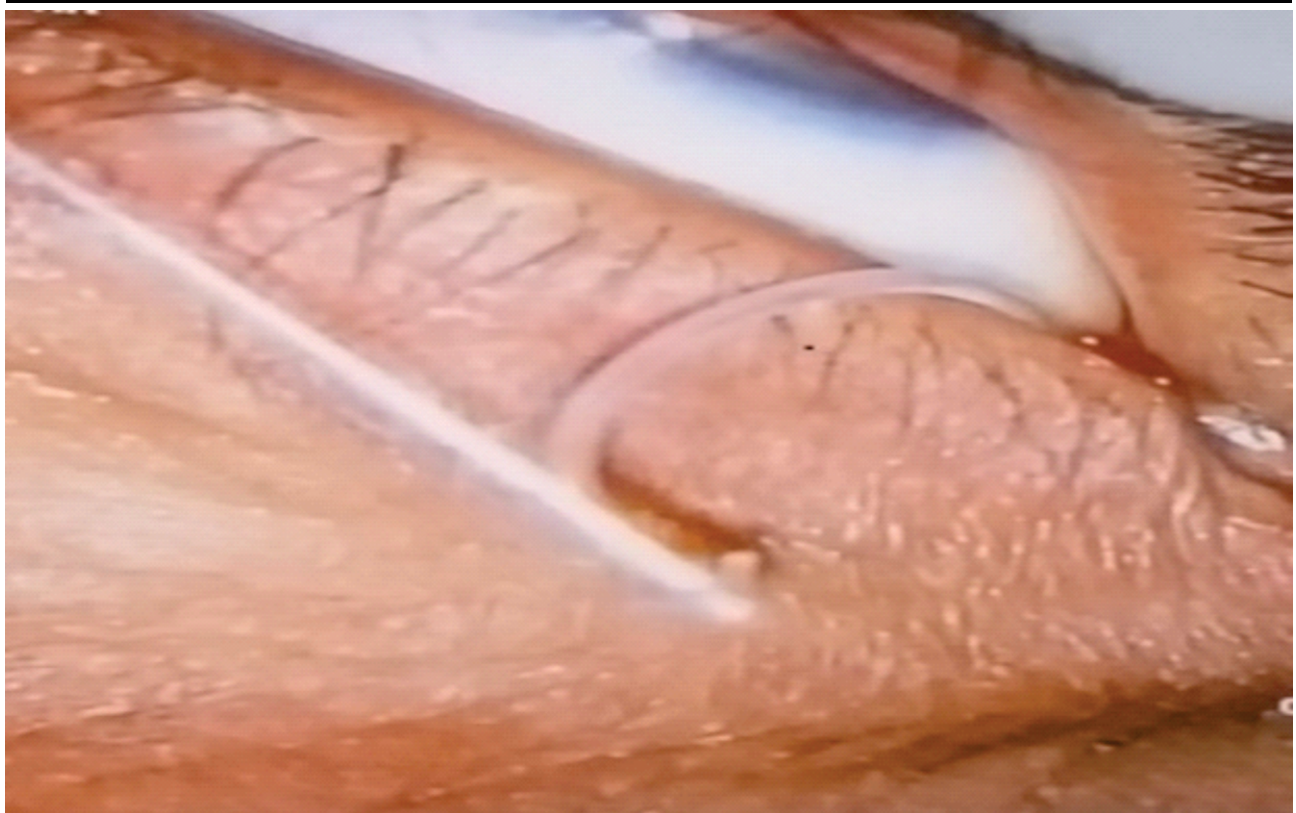


Fig 1: Bicanalicular stent passed through lower punctum

Discussion

Proximal punctal stenosis is one of the main and important causes of epiphora affecting many adult patients. Stenosis of puncti when diagnosed clinically are most frequently associated with obstruction of canaliculi.^{1,4-6} Many ocular surface diseases can cause epiphora, so a careful clinical examination is needed to find the etiological factor. In literature, various methods have been

documented to treat proximal punctal stenosis. Previously, 3 snip was a very frequently choice of method to be performed to relieve epiphora, but it was done multiple times due to fibrosis of the posterior wall.^{6,7,8}

Fulcher et al. in one of their study on silicone intubation, reported an improvement of symptoms in 54.3% (a transient improvement in 10%, a partial improvement in 14.3%, and no improvement in

21.4%). A much better outcome was seen in patients with canalicular obstruction, with complete resolution of symptoms in 75.9%.^{6,7,8,9} This also corresponds with our study results of successfully treating patients with proximal punctal stenosis with self-retaining auto stable stents.

On comparing this study with the studies present in the literature, few differences were noticed. Perry et al, in one of their study on proximal duct obstruction, which was treated by balloon dacryoplasty, dilatation with balloon catheter followed by silicon intubation was done.⁹

Veloudios et al. in their study of complication rate due to stents in acquired and congenital punctal stenosis treated with silastic stents, observed that there was tube prolapsed, extrusion, punctal erosion, conjunctival irritation and tube blockage due to dirty debris noticed in 41% of patients at 3 months follow up.¹⁰ However, no such complications were noticed in our study except of early tube extrusion in one case after 1 month of intubation due to the patient's own finger trauma.

In the literature review, many of the studies have been done to see the anatomical, functional success rates among patients with proximal punctal stenosis treated with bicanalicular self-retaining stents alone with patient satisfaction. We also noticed anatomical and functional success rate in our study.

Mimura et al. observed 94.6% success rate of proximal punctal stenosis treated with Nanchaku.¹¹⁻¹³

This is also comparable with our study results. Most of the studies in literature regarding the treatment of proximal punctal stenosis are conducted on a retrospective design that considered patients with large variations in clinical characteristics and demographics. In our study, apart from the prospective study design, we also enrolled patients with proximal punctal stenosis and excluded patients having a history of traumatic or postsurgical conditions.^{14,15,16,17}

In our study, we have discussed the new advancement and technique and their effects of bicanalicular auto-stable self-retaining stents in proximal punctal stenosis along with canalicular stenosis. The stents were left in place for 6 weeks and were removed from the office. Functional and anatomical success rate was observe dup to 06

months.

Ziahossein et al. in their study treated epiphora with botulinum toxin injection in lacrimal gland in adults which reduced the epiphora. This could be an alternative to our study but we did not include BTA treatment in our study because it is a temporary measure which is reversible and requires reinjections at the site of the lacrimal gland every 4-6 months.^{18,19,20}

This treatment was very much effective in relieving the patients symptoms, was less painful, and was performed under topical anesthesia as compared to other long-duration procedures, which are mostly done in general anesthesia.

Conclusion

Proximal acquired punctal stenosis, and obstruction can be effectively treated with auto-stable bicanaliculus intubation stent implantation. Proper implantation of stents can avoid spontaneous extrusion, while eye goggles post-operatively advised can reduce the extrusion rate.

Limitations of Study

We did not include a large cohort in our study. Secondly, this study was conducted in adults, limiting its implication in children.

REFERENCES

1. Silbert DI. Success rate of placement of a bicanalicular stent for partial nasolacrimal obstruction in adults under local, monitored anesthesia care and general anesthesia. *Saudi journal of ophthalmology* 2017; 31: 140-4. doi: 10.1016/j.sjopt.2017.06.002
2. Cherecheanu AP, Ghita M, Gheorghe I, Budu V. Lacrimal Stents and Intubation Systems—our expertise. *Romanian Biotechnological Letters*. 2020; 25: 1651-7. doi: 10.25083/rbl/25.3/1651.1657
3. DeParis SW, Hougen CJ, Rajaii F, Mahoney NR. Bicanalicular Intubation with the Kaneka Lacriflow for Proximal Lacrimal Drainage System Stenosis. *Clinical Ophthalmology*. 2020; 14: 915-20. doi: 10.2147/OPHTH.S248423
4. Ahmed RA, Kamal AM, Zayed MA. Evaluation of planned bicanalicular nasolacrimal tube retention in treating punctal stenosis or occlusion secondary to trachoma. *Orbit*. 2017; 36: 208–14. doi: 10.1080/01676830.2017.1337160
5. Mimura M, Ueki M, Oku H, Sato B, Ikeda T. Indications for and effects of Nunchaku-style silicone tube intubation for primary acquired lacrimal drainage obstruction. *Japanese*

- Journal of ophthalmology 2015; 59: 266–72. doi: 10.1007/s10384-015-0381-5
6. Tabatabaie SZ, Rajabi MT, Rajabi MB, Eshraghi B. Randomized study comparing the efficacy of a self-retaining bicanaliculus intubation stent with Crawford intubation in patients with canalicular obstruction. *Clinical Ophthalmology*. 2012; 6: 5-8. doi: 10.2147/OPHTH.S25172
 7. Mandour SS, Said-Ahmed KE, Khairy HA, Elsayy MF, Zaky MA. A Simple Surgical Approach for the Management of Acquired Severe Lower Punctal Stenosis. *Journal of Ophthalmology*. 2019; 14: 3561857. doi: 10.1155/2019/3561857
 8. Farag MY, Hovaghimian D, Hassanin OA, Ismail A. Effects of an auto stable bicanaliculus intubation stent in the management of acquired punctal stenosis. *Journal of the Egyptian Ophthalmological Society*. 2014; 107: 160-5. doi: 10.4103/2090-0686.148128
 9. Ting MAJ, Vahdani k. Punctoplasty combined with lacrimal stenting versus lacrimal stenting for punctal stenosis. *Eye*. 2021; 35: 2054-5. doi:10.1038/s41433-020-0999-5
 10. Chalvatzis NT, Tzamalís AK, Mavrikakis I, Tsinopoulos I, Dimitrakos S. Self-retaining bicanaliculus stents as an adjunct to 3-snip punctoplasty in management of upper lacrimal duct stenosis: a comparison to standard 3-snip procedure. *Ophthalmic Plastic & Reconstructive Surgery*. 2013; 29: 123-7. doi: 10.1097/IOP.0b013e31827f5a10
 11. Fiorino MG, Quaranta-Leoni C, Quaranta-Leoni FM. Proximal lacrimal obstructions: a review. *Acta Ophthalmologica*. 2021; 99: 701-11. doi: 10.1111/aos.14762
 12. Satchi K, McNab AA. Idiopathic Acquired Lacrimal Canalicular Obstruction. *Ophthalmic Plastic & Reconstructive Surgery*. 2019; 35: 266-8. doi: 10.1097/IOP.0000000000001225
 13. Ali MJ, Mishra DK, Baig F, Lakshman M, Naik MN. Punctal stenosis: histopathology, immunology, and electron microscopic features-a step toward unraveling the mysterious etiopathogenesis. *Ophthalmic Plastic & Reconstructive Surgery*. 2015; 31: 98-102. doi: 10.1097/IOP.0000000000000204
 14. Starks VS, Yoon MK. Acquired Obliteration of the Proximal Lacrimal Drainage System. *Ophthalmic Plastic & Reconstructive Surgery*. 2019; 35: 342-5. doi: 10.1097/IOP.0000000000001244
 15. Nesaratnam N, Emeriewen K, Smith J, David B, Wawrzynski J, Sharma A, et al. Scaling the punctum and canaliculus in patients undergoing punctoplasty surgery: A prospective cohort study. *Orbit*. 2017; 36: 436-40. doi: 10.1080/01676830.2017.1343857
 16. Kashkouli MB, Pakdel F, Kiavash V. Assessment and management of proximal and incomplete symptomatic obstruction of the lacrimal drainage system. *Middle East African Journal of Ophthalmology*. 2012; 19: 60-9. doi: 10.4103/0974-9233.92117
 17. Quaranta-Leoni FM, Fiorino MG, Serricchio F, Quaranta-Leoni F. Management of proximal lacrimal obstructions: A Rationale. *Acta Ophthalmologica*. 2021; 99: e569-e75. doi: 10.1111/aos.14632
 18. Krakhovetskiy NN, At Kova EL. Lakotsistorinostomiya v lecheniiobliteratsiiigorizontal'nogootdelaslezootvodyashchikh putei [Conjunctival dacryocystorhinostomy in the treatment of proximal lacrimal drainage obstruction]. *Vestn Oftalmol*. 2020; 136: 65-9. Russian. doi: 10.17116/oftalma202013606165.
 19. Eroglu FC, Sekeroglu MA, Ceran TH, Simsek M, Hondur G. Evaluation of lacrimal drainage system in Pseudoexfoliation syndrome. *Eye*. 2022; 36: 2094-8. doi: 10.1038/s41433-021-01799-1.
 20. Kaynak P, Karabulut GO, Ozturker C, Fazil K, Arat YO, Perente I, et al. Comparison of botulinum toxin-A injection in lacrimal gland and conjunctivodacryocystorhinostomy for treatment of epiphora due to proximal lacrimal system obstruction. *Eye*. 2016; 30: 1056-62. doi: 10.1038/eye.2016.88