

## CASE REPORT

### Choreiform-Ballistic Movements Due to Endocrine Deficiencies

Maryam Haroon

#### ABSTRACT

Choreiform-ballistic movements are often associated with lesions in the basal ganglia and subthalamic nucleus. For a patient with dancing movements, hyperglycemia might be an initial presentation. We hereby present a case of a young 19 years old girl already on insulin and presented with the sub-acute onset of abnormal movements. The purpose of this case report was to elaborate the possibility of choreiform movements as a rare presentation of endocrine deficiencies like type I diabetes in association with pseudohypoparathyroidism as well as the role of insulin, calcium, and vitamin D analogues in reducing the frequency and severity of these movements. Literature review showed a similar presentation with hyper-osmolar non-ketotic coma / hyper-osmolar hyperglycemic state (HONK/HHS) secondary to type 2 diabetes mellitus in middle and old-aged patients but not reported so far in young patients having type I diabetes mellitus with other underlying endocrine abnormalities.

**Keywords:** *Basal Ganglia, Choreiform Movements, Intact Parathormone Level (iPTH), Pseudohypoparathyroidism, Type 1 Diabetes Mellitus.*

**How to cite this:** Haroon M. *Choreiform-Ballistic Movements Due to Endocrine Deficiencies. Life and Science. 2022; 3(4): 203-205. doi: <http://doi.org/10.37185/LnS.1.1.274>*

This work is licensed under a Creative Commons Attribution-NonCommercial 4.0 International license. (<https://creativecommons.org/licenses/by-nc/4.0/>). Non-commercial uses of the work are permitted, provided the original work is properly cited.

#### Introduction

Evaluating patients presenting to the emergency department with abnormal movements could be challenging. Dancing movements like choreiform or ballistic type are more common than hypo kinetic disorders. The clinical presentation can be acute or insidious, characterized by purposeless, irregular and involuntary jerky movements of extremities accompanied by facial grimacing. Chorea/ballismus/hemiballismus have often been associated with lesions in basal ganglia (caudate and lenticular nucleus) and sub-thalamic nuclei. Possible for a patient with chorea-ballismus to have hyperglycemia at initial presentation along with underlying hypocalcemia secondary to endocrine deficiencies or hormones-specific receptor abnormalities. We present a case of 19 years old girl who was on insulin therapy and presented with sub-acute onset of abnormal movements of her right

upper limb with predominant involvement of the hand. Laboratory parameters showed derangement in total body calcium and glucose homeostasis milieu originating as rare but unique hyper-kinetic movements disorder so-called dancing movements. These movements can be inherited acquired secondary to metabolic/biochemical disorders, iatrogenic, or immune-mediated. This case report highlights the possibility of mixed endocrine deficiencies as a cause of choreiform-ballistic type movements along with emphasizing improvement in symptom control by substituting deficient hormones' analogues such as calcium supplements and vitamin D analogue besides injection insulin administration.

#### Case report

A 19-years-old Asian girl presented in emergency department of our hospital with choreiform-ballistic type movements of her right upper limb for last few hours. She was a type 1 diabetic for the last 7 years and compliant to the insulin regime but had a history of dietary non-compliance and behavioral changes. She had ketoacidosis secondary to uncontrolled hyperglycemia along with hypocalcemia secondary to either pseudohypoparathyroidism. At presentation, her vital signs were normal except RR 28 breaths/min, random blood sugar level 545mg/dl,

*Department of Medicine*

*Services Institute of Medical Services (SIMS), Lahore, Pakistan*

*Correspondence:*

*Dr. Maryam Haroon*

*Department of Medicine*

*Services Hospital Lahore, Pakistan*

*E-mail: [drkhan1224@yahoo.com](mailto:drkhan1224@yahoo.com)*

*Funding Source: NIL; Conflict of Interest: NIL*

*Received: Jan 10, 2022; Revised: May 08, 2022*

*Accepted: Jul 12, 2022*

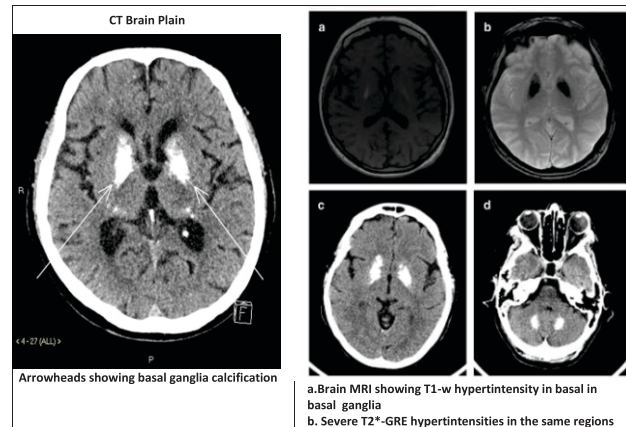
thin lean with body weight 50 kg, height 5 ft and 2 inches, well cooperated, oriented to time and space with involuntary, rapid, flying/dancing movements restricted to right-sided upper limb. Her general and systemic examinations, including the neurological examination (cerebellum and dorsal column), were unremarkable with no history of delayed milestones, congenital anomalies, inherited disorders, or hormonal problems. Arterial blood gases showed PH: 7.106, PCO<sub>2</sub>:20, PO<sub>2</sub>:85, HCO<sub>3</sub>: 8. The complete blood count revealed Hb 11, WBCs 8, PLTs 200. Creatinine: 0.9, serum Na: 135mEq/L, serum K: 5.0, serum calcium: 6.0, serum PO<sub>4</sub>: 4.2, serum chloride: 102, serum Mg<sub>2</sub>:2.4, AST: 20, ALT: 15, Bilirubin: 0.4, ALP: 135.

On urine complete exam PH: 5.8, pus cells: 2-3, Sp gravity: 1.020, ketones: +++, cast/crystals/organisms:nil.

ECG, chest X-ray, and ultrasound abdomen and pelvis were normal.

CT brain was performed and findings were consistent with consistent hyperintensities, likely calcification at the level of basal ganglia (Para-thalamic areas) (Figure 1). Fluid resuscitation started with potassium replacement in accordance with diabetic ketoacidosis (DKA) protocols, and insulin infusion given at standard dose (wt. adjust). DKA got improved but dancing movements persisted. Meanwhile, calcium gluconate was administered intravenously, and oral vitamin D analogue (alfacalcidol) supplementation started without nerve stabilizers (tetrabenazines). Within a day, her choreiform-ballistic movements got relieved, more necessary workup was planned, and the patient was discharged. A follow-up meeting was arranged with essential laboratory workup. Magnetic resonance imaging (MRI) brain with contrast further ruled out atrophic or neurodegenerative changes and space occupying lesions (SOL) as a cause of these dancing movements.

Serum intact PTH: 150pg/ml (normal range 10-55p). Though suspicion of pseudohypoparathyroidism was on top of the list but due to non-availability of genetic screening or studies in our setup, urinary phosphate excretion along with urinary cyclic AMP were measured in response to intravenous recombinant PTH analogue administration, and surprisingly mild phosphate excretion were detected



**Fig 1: Radiological images showing basal ganglia calcification**

in subsequent urinary samples.

## Discussion

Dancing (choreiform-ballismus) movements are characterized by spontaneous involuntary movements, muscular weakness, and uncoordinated movements. These movements can be classified as idiopathic, hereditary, or acquired and are caused by metabolic, vascular, structural disorders, or hypoxic-ischemic events.<sup>1</sup> Can be infection, drug induced, or immune mediate affecting basal ganglia and subthalamic nuclei. Such movements may be the presenting feature of endocrine deficiencies.<sup>2</sup> Hyperglycemia may be present at initial presentation<sup>3</sup>, sometimes in association with underlying problems in other hormones milieu, most commonly thyroid and parathyroid systems. The pathogenesis of choreiform-ballistic type movements with ketotic hyperglycemia along with pseudohypoparathyroidism is poorly understood.<sup>4</sup> In DKA, ketones especially acetoacetate, is rapidly deleted, leading to cellular dysfunction<sup>5</sup>, also, deposition of calcium in cerebral gray nuclei triggers functional impairment of inhibitory pathways of basal ganglia responsible for making body movements to be voluntary and refined.<sup>6</sup> Prognosis of such movements is excellent.<sup>7</sup> When mixed deficiencies are detected and subsequently corrected, dancing movements are usually resolved within days without the use of dopamine receptor antagonists.<sup>8</sup> In this case report, patient's hyperkinetic choreiform movements resolved dramatically after treatment of DKA secondary to

uncontrolled hyperglycemia with simultaneous administration of calcium and vitamin D analogue. This illustrates that acute choreiform-ballistic type movement disorder is treatable with excellent prognosis if compliance to treatment is assured. In patients with chorea-ballismus/hemiballismus with ketotic hyperglycemia in primary diabetes mellitus, CT and MRI images show either unilateral or bilateral caudate-lenticular nuclei lesions related to petechial hemorrhage or demyelination. However in our patient CT head revealed basal ganglia calcification. Thus serum glucose as well as serum calcium should be measured in all patients with new onset of choreiform-ballistic movements as they both are reversible cause of extra pyramidal movements disorder.

### Conclusion

Choreiform movements are unique but rare manifestations of changes in the hormonal milieu. In young patients, hyperglycemia secondary to insulin deficiency can be an initial presentation associated with abnormalities in the functioning of other endocrine organs such as parathyroid; however, symptoms get improved with the appropriate replacement of deficient hormones.

### Consent

Written informed consent was obtained from the patient's legal guardian for publication of this manuscript and accompanying images. A copy of the written consent is available for review by the Editor-in-Chief of the respected journal.

### Abbreviations

Na: sodium, K: potassium, PTH: parathyroid hormone/ parathormone, Mg<sup>2+</sup>: magnesium, ALT:

alanine aminotransferase, AST: aspartate aminotransferase, ALP: alkaline phosphatase, DKA: diabetic ketoacidosis, ECG: electrocardiogram, AMP: adenosine monophosphate, WBCs: white cell counts, PLTs: platelets, PH: the potential of hydrogen, HHS: hyper-osmolar hyperglycemic state, HONK: hyper-osmolar non-ketotic coma.

### REFERENCES

1. Hashimoto Ki, Ito Y, Tanahashi H, Hayashi M, Yamakita N, Yasuda K. Hyperglycemic chorea-ballism or acute exacerbation of Huntington's chorea? Huntington's disease unmasked by diabetic ketoacidosis in type 1 diabetes mellitus. *The Journal of Clinical Endocrinology & Metabolism*. 2012;97: 3016-20.
2. Chowdhury F, Ross AG, Islam MT, McMillan NA, Qadri F. Diagnosis, Management, and Future Control of Cholera. *Clinical Microbiology Reviews*. 2022;35: e00211-21.
3. Insogna KL. Primary hyperparathyroidism. *New England Journal of Medicine*. 2018;379:1050-9.
4. Hergert DC, Sanchez-Ramos J, Cimino CR. Awareness of chorea in Huntington's disease. *Journal of Huntington's Disease*. 2020;9:99-103.
5. Bilezikian JP, Bandeira L, Khan A, Cusano NE. Hyperparathyroidism. *The Lancet*. 2018;391:168-78.
6. Maiti A, Chatterjee S. Neuropsychiatric manifestations and their outcomes in chronic hypocalcaemia. *Journal of the Indian Medical Association*. 2013;111:174-7.
7. Randazzo A. Stressed Out and Stressed In: Regulating the Stress Response at an Endocrine Level through Dance/Movement Therapy. 2022.
8. Patki R, Douglas R, Rimareva N, Kondamudi N. Uncontrollable movements of right upper and lower extremities in a child: A diagnostic puzzle. *Journal of the American College of Emergency Physicians Open*. 2021;2: e12497.